




Women's Health

Kristen Jones, DO
Osteopathic Faculty
St. Luke's Family Medicine Residency
Bethlehem, PA

ACOFP exam

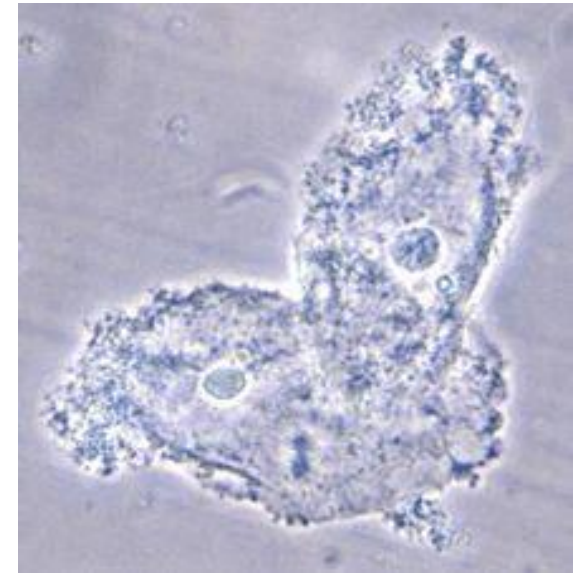
- Women's Issues (4% of test – OB/GYN = 4%) between 4-6%
- **Common Topics**
- Vaginal Discharge
- Pelvic Pain
- Cancer risk factors
- Menstrual disorders
- Breast Discharge
- Eating disorders
- Osteoporosis
- HRT


- 
- 23 yo with vaginal discharge. Sexually active. Pelvic exam reveals:
 - Thin gray-white discharge, pH 5, a strong fishy odor is present when KOH is added to the discharge.
 - A) Bacterial Vaginosis
 - B) Gonorrhea
 - C) Chlamydia
 - D) Candida
 - E) Physiologic Discharge

- 23 yo with vaginal discharge. Sexually active. Pelvic exam reveals:
- Thin gray-white discharge, **pH 5**, a strong **fishy odor** is present when KOH is added to the discharge.
- **A) Bacterial Vaginosis**
- B) Gonorrhea
- C) Chlamydia
- D) Candida
- E) Physiologic Discharge

Bacterial Vaginosis

- **pH >4.5**
- +Whiff Test
- +Clue cells – epithelial cells with adherent bacteria.
- Caused by Gardnerella
- Treat with Flagyl 500mg po q12hx7 days (safe in pregnancy)

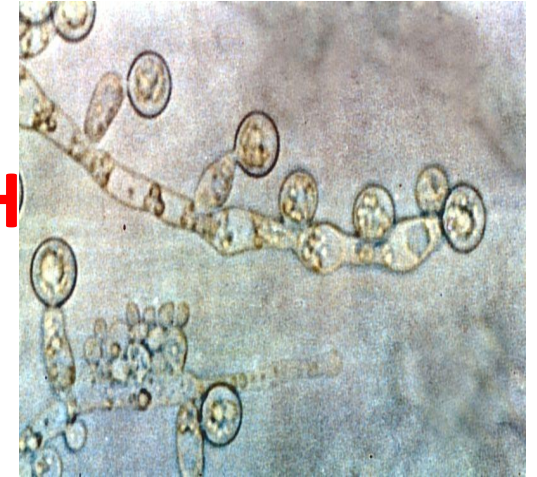


- 
- 23 yo with vaginal discharge. Sexually active. Pelvic exam reveals:
 - pH <4, vulvar erythema, thick white discharge
 - Most likely cause is:
 - A) Bacterial Vaginosis
 - B) Trichomonas
 - C) Chlamydia
 - D) Candida
 - E) Physiologic Discharge

- 23 yo with vaginal discharge. Sexually active. Pelvic exam reveals:
- pH <4.5, **vulvar erythema**, thick white discharge
- Most likely cause is:
- A) Bacterial Vaginosis
- B) Trichomonas
- C) Chlamydia
- **D) Candida**
- E) Physiologic Discharge

Vaginal Candidiasis

- pH <4.5
- **Budding yeast and hyphae on KOH**
- Thick white, chunky discharge
- Vulvar erythema and pruritis
- Treat with PO fluconazole 150mg po x1
- Treat with **PV** clotrimazole or miconazole for 7 days during **pregnancy**

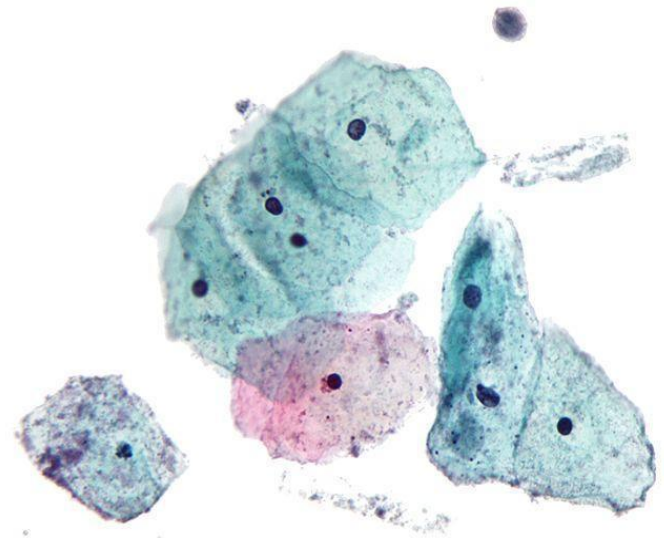



- 
- 23 yo with vaginal discharge. Sexually active. Pelvic exam reveals:
 - pH >4.5, motile organisms on wet mount
 - Most likely cause is:
 - A) Bacterial Vaginosis
 - B) Trichomonas
 - C) Chlamydia
 - D) Candida
 - E) Physiologic Discharge

- 23 yo with vaginal discharge. Sexually active. Pelvic exam reveals:
 - **pH >4.5, motile organisms** on wet mount
 - Most likely cause is:
 - A) Bacterial Vaginosis
 - **B) Trichomoniasis**
 - C) Chlamydia
 - D) Candida
 - E) Physiologic Discharge

Trichomoniasis

- pH >4.5
- motile flagellated organisms on wet mount
- Discharge can be clear, white, yellow or green
- Treat with metronidazole 2 gm po x 1 dose



- 
- 13 yo with vaginal discharge. Sexually active. Pelvic exam reveals:
 - pH <4.5, many WBCs on wet mount, no other findings
 - Most likely cause is:
 - A) Bacterial Vaginosis
 - B) Trichomoniasis
 - C) Chlamydia
 - D) Candida
 - E) Physiologic Discharge

- **13 yo** with vaginal discharge. Sexually active. Pelvic exam reveals:
 - pH <4.5, many WBCs on wet mount
 - Most likely cause is:
 - A) Bacterial Vaginosis
 - B) Trichomoniasis
 - C) Chlamydia
 - D) Candida
 - **E) Physiologic Discharge**



Physiologic Discharge

- pH <4.5
- Leukorrhea
- predominance of WBCs on wet mount
- typical several months before the onset of menses – preteen-teenage
- No treatment

- 23 yo with L adnexal pelvic pain, noticed some thick yellow vaginal discharge last week. Sexually active. Previously tested positive for Gonorrhea two years ago and was treated. Pelvic exam shows cherry red cervix, severe cervical motion tenderness and thick discharge from the cervical os. T = 100.6, BP 135/90, HR 90, RR 14
- Next step:
 - a) Ultrasound
 - b) IM ceftriaxone + oral doxycycline
 - c) Ultrasound with doppler flow
 - d) CT without contrast

- 23 yo with L adnexal pelvic pain, noticed some thick yellow vaginal discharge last week. Sexually active. Previously tested positive for Gonorrhea 2 years ago and was treated. Pelvic exam shows cherry red cervix, severe cervical motion tenderness and thick discharge from the cervical os. T = **100.6**, BP 135/90, HR 90, RR 14
- Next step:
 - a) Ultrasound
 - b) IM ceftriaxone + oral doxycycline**
 - c) Ultrasound with doppler flow
 - d) CT without contrast

Pelvic Inflammatory Disease

- Usually caused by GC or CT
- Cervical motion tenderness
- Can cause infertility, ectopic pregnancy
- Fitz-hugh-curtis
- **Ceftriaxone** 250mg **IM** x1 PLUS **doxycycline** 100mg **orally** BID for 14 days **+/- metronidazole** 500mg orally BID for 14 days (first line)
- IV 3rd generation cephalosporin with doxy +/- metronidazole as above (severe)

- 23 yo with L adnexal pelvic pain of sudden onset. Associated N/V. Scant thin vaginal discharge. Sexually active. Previously tested positive for gonorrhea 2 years ago and was treated. Pelvic exam reveals left adnexal tenderness. T = 99.0, BP 135/90, HR 90, RR 14
- Next step:
 - a) Ultrasound
 - b) IM ceftriaxone + oral doxycycline
 - c) Ultrasound with doppler flow
 - d) CT without contrast

- 23 yo with L adnexal pelvic pain of **sudden onset**. Associated **N/V**. Scant thin vaginal discharge. Sexually active. ~~Previously tested positive for gonorrhea 2 years ago and was treated.~~ Pelvic exam reveals left adnexal tenderness. T = **99.0** other VSS.

- Next step:

a) Ultrasound

b) IM ceftriaxone + oral doxycycline

c) Ultrasound with doppler flow

d) CT without contrast

Ovarian Torsion

- Sudden onset of sharp, unilateral lower abdominal pain,
- 70% of cases accompanied by nausea and vomiting.
- Fever if necrosis of ovary
- Ultrasound with doppler to see if blood flow present to ovary
- Treatment is surgery

- 23 yo with L adnexal/suprapubic pelvic pain. Worse during intercourse. No vaginal discharge but +menorrhagia. Pelvic exam reveals mild uterine tenderness and slightly enlarged uterus. T = 99, BP 135/90, HR 90, RR 14
- Next step:
 - a) Ultrasound
 - b) IM ceftriaxone + oral doxycycline
 - c) Ultrasound with doppler flow
 - d) CT without contrast

- 23 yo with L adnexal/suprapubic pelvic pain. Worse during **intercourse**. No vaginal discharge but **+menorrhagia**. Pelvic exam reveals mild uterine tenderness and slightly enlarged uterus. T = 99, BP 135/90, HR 90, RR 14

- Next step:

a) Ultrasound

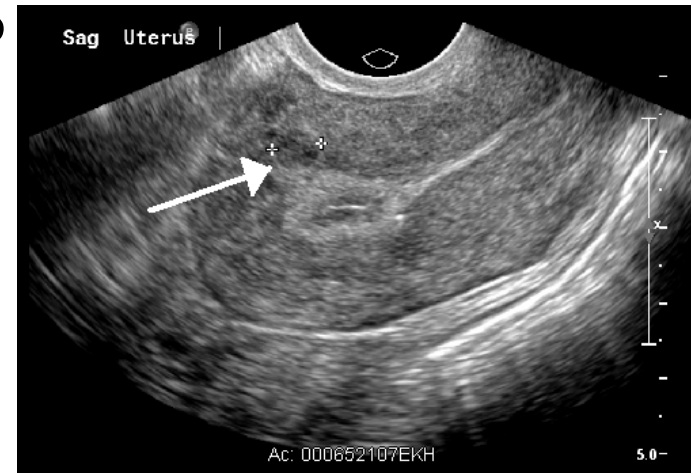
b) IM ceftriaxone + oral doxycycline

c) Ultrasound with doppler flow

d) CT without contrast

Fibroids


- Bleeding between periods
- Heavy bleeding during period
- Periods last longer than normal
- Polyuria
- Pelvic cramping or pain with periods
- Feeling fullness or pressure in lower belly
- Pain during intercourse
- **Myomectomy** is the treatment of choice if patient wants to have children.
- Other options include OCP, embolization, observation





Other causes of Pelvic Pain

- Don't forget Appendix and UTI!

- 
- Risk factors for endometrial cancer include
 - a) HPV
 - b) Smoking
 - c) Endometriosis
 - d) Unopposed estrogen



- Risk factors for endometrial cancer include

- a) HPV

- b) Smoking

- c) Endometriosis

- d) Unopposed estrogen**

Endometrial Cancer

- Presents with bleeding after menopause
- Risk Factors :
- early menarche, late menopause, nulliparity, personal or family history of colon or reproductive system cancer, metabolic syndrome, **obesity**, DM, HTN, **PCOS**, endometrial hyperplasia, **unopposed estrogens**, tamoxifen, age, prior pelvic irradiation.
- DECREASED RISK WITH SMOKING



- Risk factors for Ovarian cancer include

- a) HPV

- b) Alcohol use

- c) Endometriosis

- d) Unopposed progestin

- e) Combined HRT



- Risk factors for Ovarian cancer include

- a) HPV

- b) Alcohol use

- c) Endometriosis**

- d) Unopposed progestin

- e) Combined HRT

Ovarian Cancer

- No screening test
- Presents with **bloating, cul de sac nodularity** on exam
- Risk factors :
- family history (90% sporadic), infertility, endometriosis, smoking (mucinous only), unopposed estrogen



- Risk factors for Cervical cancer include

- a) HPV

- b) Alcohol use

- c) Endometriosis

- d) Unopposed estrogen

- e) Combined HRT

- 
- Risk factors for cervical cancer include

a) **HPV**

b) Alcohol Use

c) Endometriosis

d) Unopposed estrogen

e) Combined HRT

Cervical Cancer

- Pap screening guidelines – start at 21, reflex HPV during 20s, cotesting during thirties.
- Post coital bleeding is most common symptom
- Usually asymptomatic
- **HPV!!**
- Other risk factors (**things that increase risk of HPV**) : early coitarche, multiple sexual partners, unprotected sex, history of STD, non barrier methods of birth control, high parity, **cigarette smoking**, immunosuppression, **DES exposure in utero**.



- Risk factors for breast cancer include

- a) HPV

- b) Smoking

- c) Endometriosis

- d) Unopposed estrogen

- e) Combined HRT



- Risk factors for breast cancer include

- a) HPV

- b) Smoking

- c) Endometriosis

- d) Unopposed estrogen

- e) Combined HRT**

Breast Cancer

- Presentation – mass, pain, erythema
- Risk Factors:
- **family history, nulliparity**, early menarche, advanced age, prior chest radiation, DES, **HRT**, high ETOH use, high BMI, physical inactivity.

- 23 yo presents with abnormal menses. She states that she has Periods “too much”. Upon further questioning she states she bleeds a moderate amount for 4 days every 18 days. She experiences breast tenderness and mild abdominal pain on the same cycle. This is described as:


- A) Menorrhagia
- B) Metrorrhagia
- C) Menometrorrhagia
- D) Polymenorrhea
- E) Dysmenorrhea


- 23 yo presents with abnormal menses. She states that she has Periods “too much”. Upon further questioning she states she bleeds a moderate amount for 4 days every 18 days. She experiences breast tenderness and mild abdominal pain on the same cycle. This is described as:

- A) Menorrhagia
- B) Metrorrhagia
- C) Menometrorrhagia
- **D) Polymenorrhea**
- E) Dysmenorrhea

Disorders of Menstruation

- Menorrhagia - bleeding is abnormally heavy or prolonged
- Dysmenorrhea – Menstrual period is abnormally painful
- Metrorrhagia –bleeding at irregular intervals
- Menometrorrhagia - prolonged or excessive uterine bleeding occurs irregularly and more frequently than normal
- Polymenorrhea - cycles with intervals of 21 days or fewer
- Oligomenorrhea - infrequent, often light menstrual periods (intervals exceeding 35 days)
- Amenorrhea –Absence of menstruation in a woman of reproductive age. Primary if never starts. Secondary if had regular periods and then stopped

- 
- A 45 year old female presents complaining of discharge from her right breast. She states the discharge is white, thin, “like milk”. She has never been pregnant. She has never had a mammogram. The next best test is:
 - A)Ultrasound
 - B)Mammogram
 - C)Prolactin
 - D)TSH

- 
- A 45 year old female presents complaining of discharge from her right breast. She states the discharge is white, thin, “like milk”. She has never been pregnant. She has never had a mammogram. The next best test is:
 - A)Ultrasound
 - B)**Mammogram**
 - C)Prolactin
 - D)TSH

Breast discharge

- Galactorrhea – should be only with compression, bilateral, no mass, no blood
 - Hyperthyroidism – low TSH, other signs of increased thyroid
 - Elevated prolactin – pituitary tumor
 - Medications – phenothiazines, TCA, amphetamines, OCPs, cimetidine, metoclopramide, verapamil
 - pregnancy
- Bloody, spontaneous, unilateral, breast mass – intraductal papilloma, ductal ectasia, malignancy, mastitis or abscess
- Other – non milky, normal mammogram, TSH, prolactin – physiologic


,


- A 18 yo female presents after an episode of “passing out” during exercise. She states that she felt “light headed/dizzy” and had to sit down. She is a dancer and was in rehearsal. You notice that she had a BMI of 28 3 years ago and her BMI currently is 21. Her mother states that the patient has been “constipated” and has asked her mom to buy laxatives. Upon questioning she admits that she has had several new cavities. Associated with this condition:
 - A) Hair loss
 - B) Decreased bone density
 - C) Mitral Valve prolapse
 - D) Hypokalemia

- A 18 yo female presents after an episode of “passing out” during exercise. She states that she felt “light headed/dizzy” and had to sit down. She is a dancer and was in rehearsal. You notice that she had a BMI of 28 3 years ago and her BMI currently is 21. Her mother states that the patient has been “constipated” and has asked her mom to buy laxatives. Upon questioning she admits that she has had several new cavities. Associated with this condition:
 - A)Hair loss
 - B)Decreased bone density
 - C)Mitral Valve prolapse
 - **D)Hypokalemia**

Eating Disorders Anorexia vs Bulimia

- Anorexia
 - hypothermia, bradycardia, orthostatic hypotension, dysrhythmias, MVP, dry skin, lanugo, hair loss, edema
 - CBT +/- SSRI
- Bulimia
 - Hypokalemia, hyponatremia, hypochloremia, hypomagnesemia, hypocalcemia, hypophosphatemia, alkalosis, hypoglycemia, increase BUN increased urine specific gravity
 - SSRI **and** CBT more effective

- 
- 71yo female whose sister just fell and broke her hip presents asking about how she can prevent this for herself. You order a central DXA scan which shows a T score of -2.0 at the hip and spine. You recommend what intervention?
 - A) Calcium supplementation alone
 - B) Swimming
 - C) Walking
 - D) A Bisphosphonate

- 
- 71yo female whose sister just fell and broke her hip presents asking about how she can prevent this for herself. You order a central DXA scan which shows a T score of -2.0 at the hip and spine. You recommend what intervention?
 - A) Calcium supplementation alone
 - B) Swimming
 - **C) Walking**
 - D) A Bisphosphonate

Osteoporosis

- Osteoporosis – CENTRAL DXA (wrist less sensitive)
 - Weight bearing exercise, calcium (1200-1500mg) vitamin D minimally 8000 IU, smoking cessation
 - Dexa scores – osteopenia = Tscore -1 - -2.5, osteoporosis as <-2.5.
 - Treatment of osteoporosis– bisphosphonates second line – calcitonin, raloxifene, teriparatide, HRT

- A 58 yo female presents complaining of “hot flashes” for several months. During the same period, her menstruation has become more sporadic. She states that her cousin had her “hormones fixed” which helped her symptoms and she wants to know if she can have “hormones” as well. Which of the follow is true about HRT?
- A) Increased risk of Coronary Artery Disease
- B) Increased risk of fracture
- C) Estrogen alone should be given to all patients to reduce the risk of endometrial cancer
- D) Decreased risk of Breast Cancer

- A 58 yo female presents complaining of “hot flashes” for several months. During the same period, her menstruation has become more sporadic. She states that her cousin had her “hormones fixed” which helped her symptoms and she wants to know if she can have “hormones” as well. Which of the follow is true about HRT?

- **A) Increased risk of Coronary Artery Disease**
- B) Increased risk of fracture
- C) Estrogen alone should be given to all patients to reduce the risk of endometrial cancer
- D) Decreased risk of Breast Cancer

Hormone Replacement Therapy

- HRT decreases vasomotor symptoms,
- Indicated for moderate to severe vasomotor symptoms,
- Decreases osteoporotic fractures.
- Increases risk of CAD, invasive breast CA, CVA, PE.
- Use lowest dose for shortest period of time.
- Contraindicated in estrogen dependent malignancies, unexplained uterine bleeding, history of VTE, CAD, CVA, active liver disease
- Use both estrogen and progestin for women with an intact uterus secondary to uterine CA risk of unopposed estrogen
- Topical estrogen for atrophic vaginitis – premarin cream, reverse vaginal atrophy, enhances blood flow, reduces pH and UTIs, can be continued as long as symptoms remain, contraindicated in hormone dependent CA (talk to oncologist)

Menopause

- Vasomotor symptoms
- venlafaxine, paroxetine, fluoxetine (<1 hot flash per day), gabapentin, clonidine
- Black cohosh/red clover – no evidence
- Evening primrose, dong quai, ginseng, wild yam - no evidence



References

- AFP
- 5 minute clinical consult
- Stedman's medical dictionary